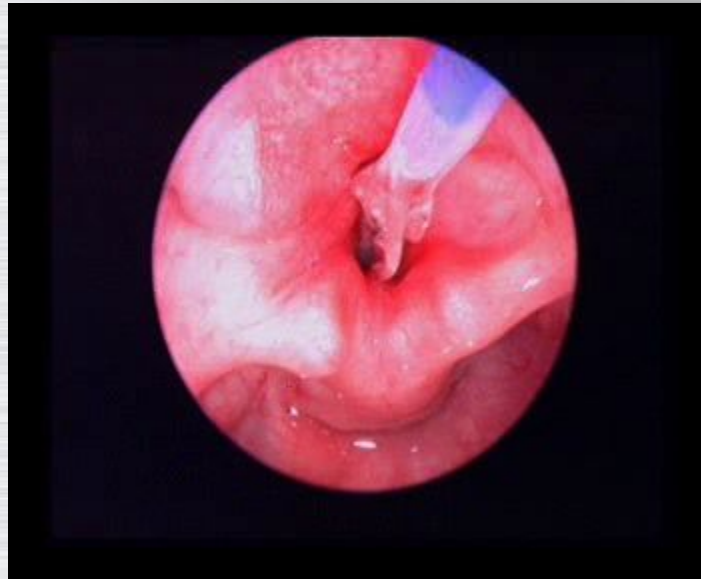


Warming up

# Endoscopic Surgery For Paediatric Laryngotracheal Stenosis



David Albert  
Great Ormond Street Hospital  
London

# Endoscopic techniques

Indications

Developing stenosis

Established stenosis

# When?

## **Developing stenosis**

Cysts/granulations

Balloon dilatation

Inject steroids / apply mitomycin

Endoscopic cricoid split

# When?

## **Before open surgery**

Divide commissure/adrenaline

## **After open surgery**

Balloon dilatation/T-tubes/stents

## **(Established stenosis)**

Recurrent stenosis – avoid repeated open

Thin web/stenosis

Posterior stenosis

# Why?

## **Concerns with existing techniques**

Avoid tracheostomy  
? improve vocal outcome  
Avoid LASER

## **Initially encouraging results**

Convergent thinking: not alone  
Concepts fit with my animal work

## **New techniques available**

Sharp division  
Radial dilatation  
12+ Bar without shearing  
Microdebrider  
Mitomycin  
Steroids  
Stents  
Lateralisation sutures

# History



60's Premature infants survive

Acquired Subglottic Stenosis

Tracheostomy



70's Open laryngeal surgery, Rib graft repair

80's Cricoid split to deal with early cases

90's Single stage laryngeal reconstruction

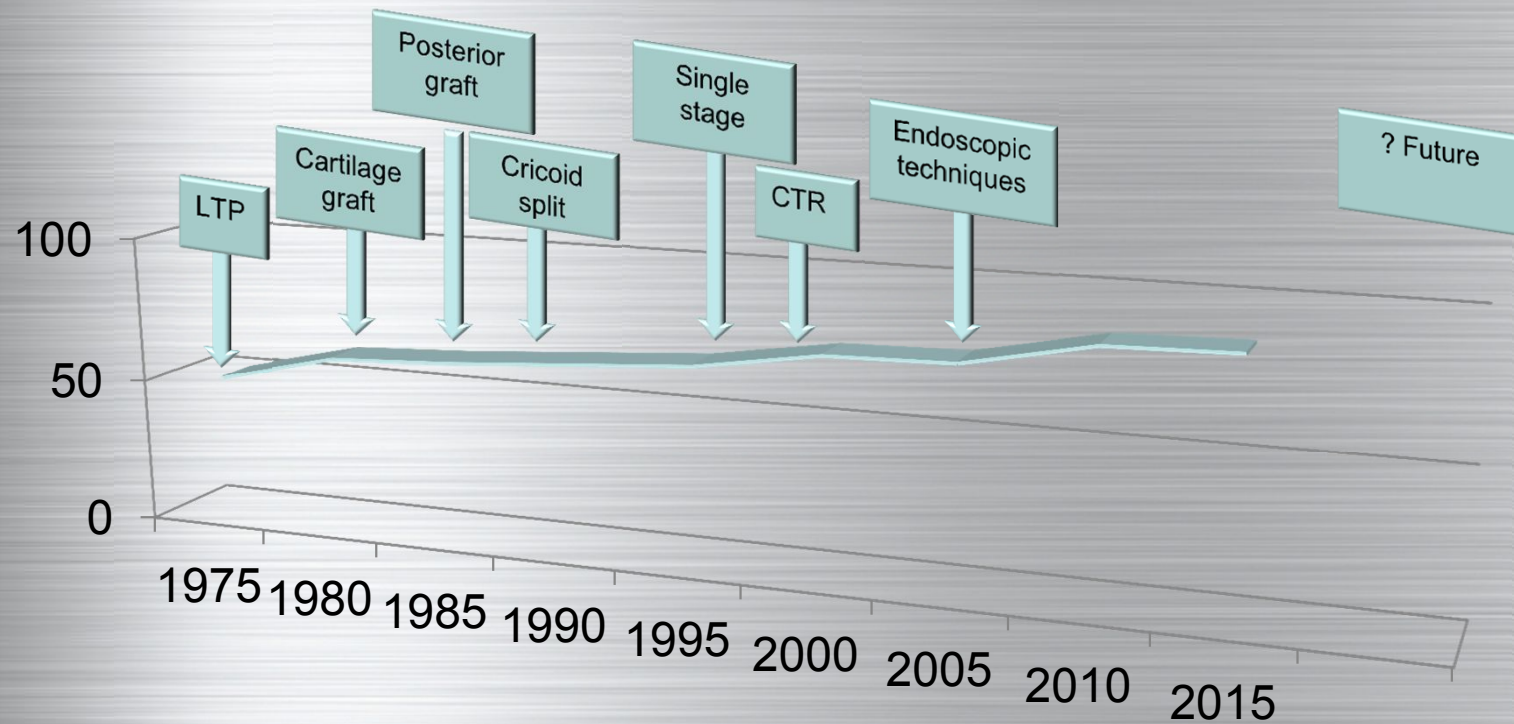
Partial cricotracheal resection



2000+ Endoscopic techniques



# Has progress reached a plateau?





# Aetiology

No single factor

Prolonged intubation

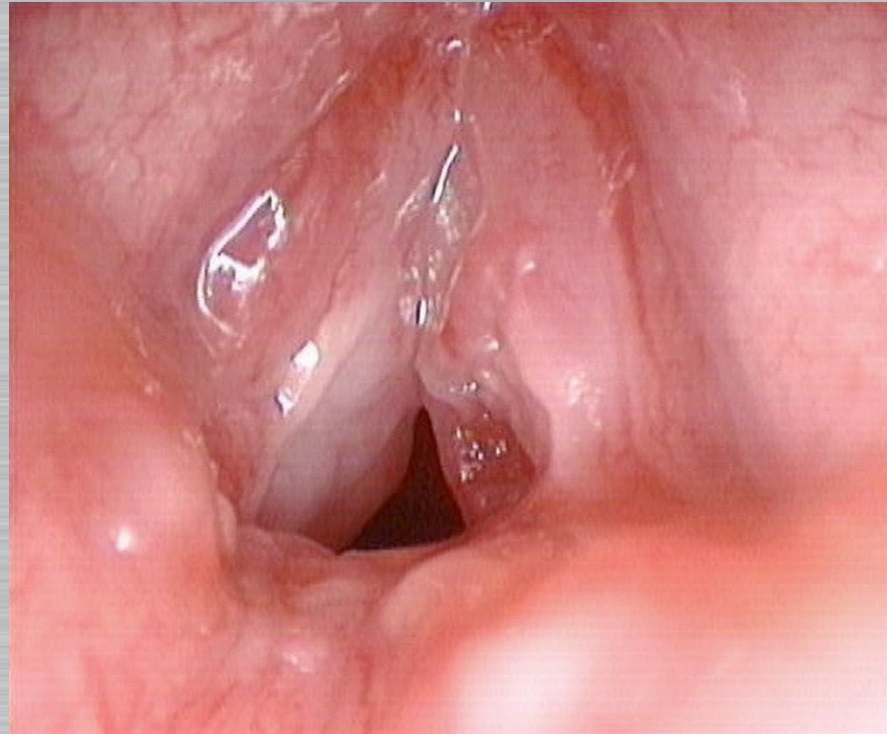
General health

Oral/nasal

Movement

? Reflux

? Initial Airway size



# Natural history

## Prevention

Greater awareness has reduced the incidence

Surfactant/steroids/non interventional ventilation

But ....very low birth weight and gestational age  
now survive

## Progression

Established mature stenosis does not in general  
“improve with age”

Children do not “grow out of it”

# Basic Endoscopic Techniques

Anaesthesia

Adrenaline

FESS style

Cut/divide/shave


Wedge resection

Balloon

Stent

Suture

Graft



# Techniques for soft developing stenosis

# Initial Techniques

Sharp removal granulations and cysts

Sharp division of stenosis and webs

Radial balloon dilatation

Microdebrider

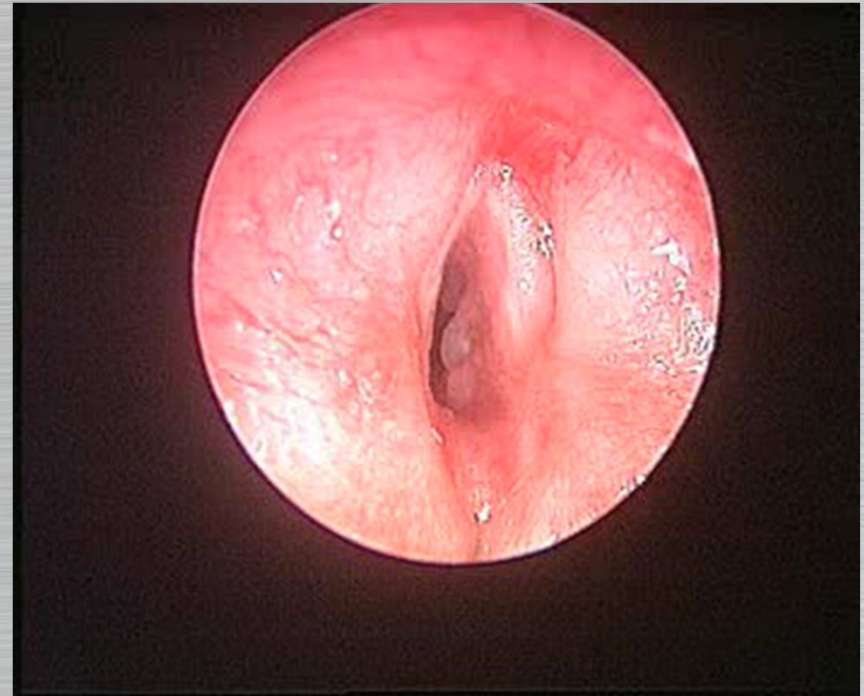
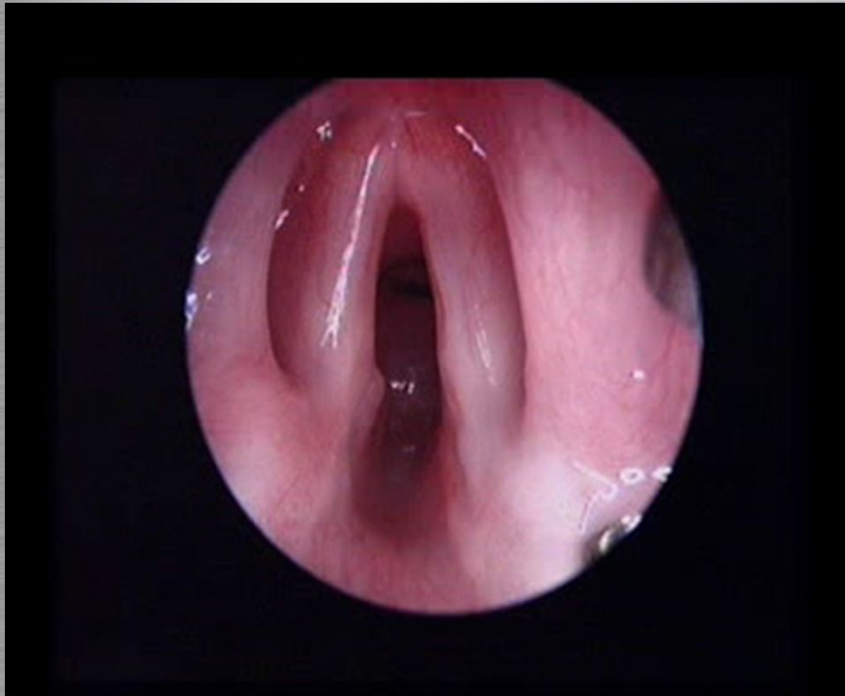
Inject steroids

Apply Mitomycin

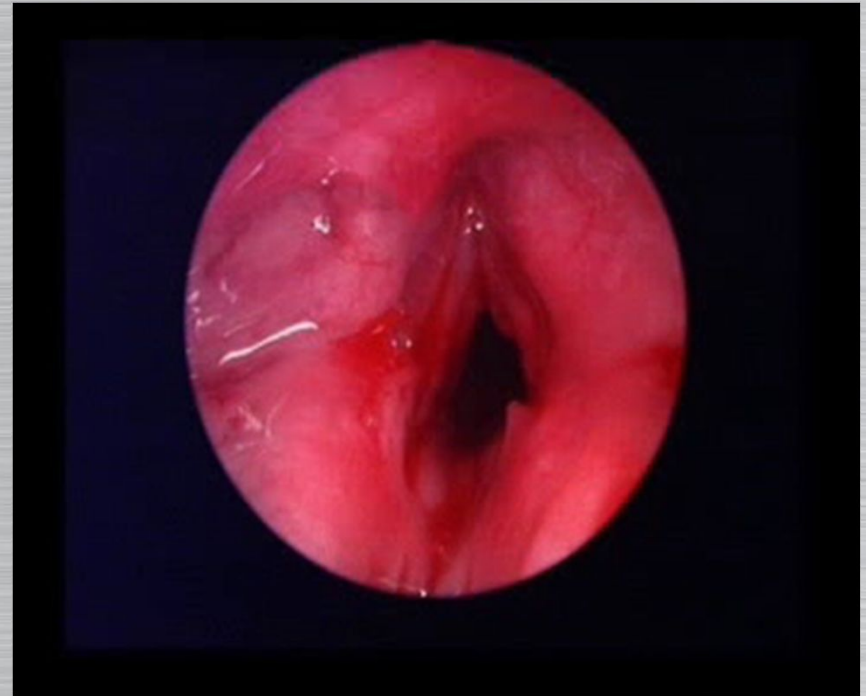
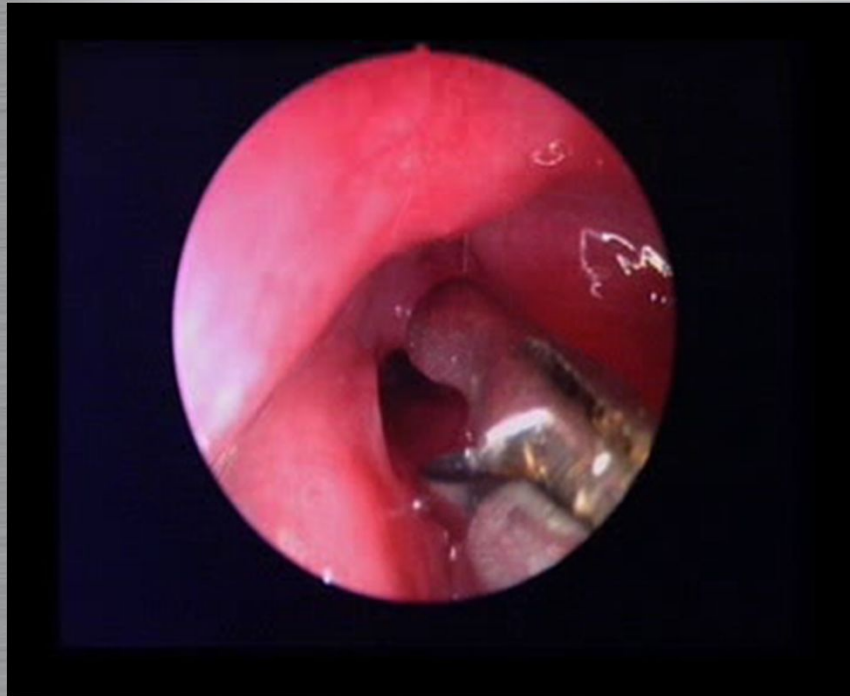
Period of quiet relaxation for the larynx




# Sharp Removal Of Cysts



# Sharp Removal Of Granulations

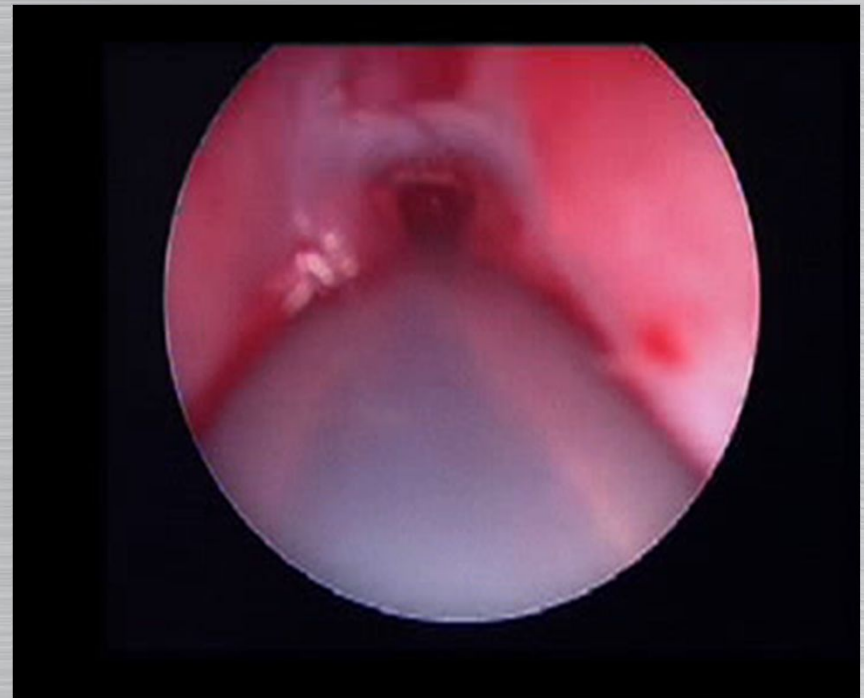
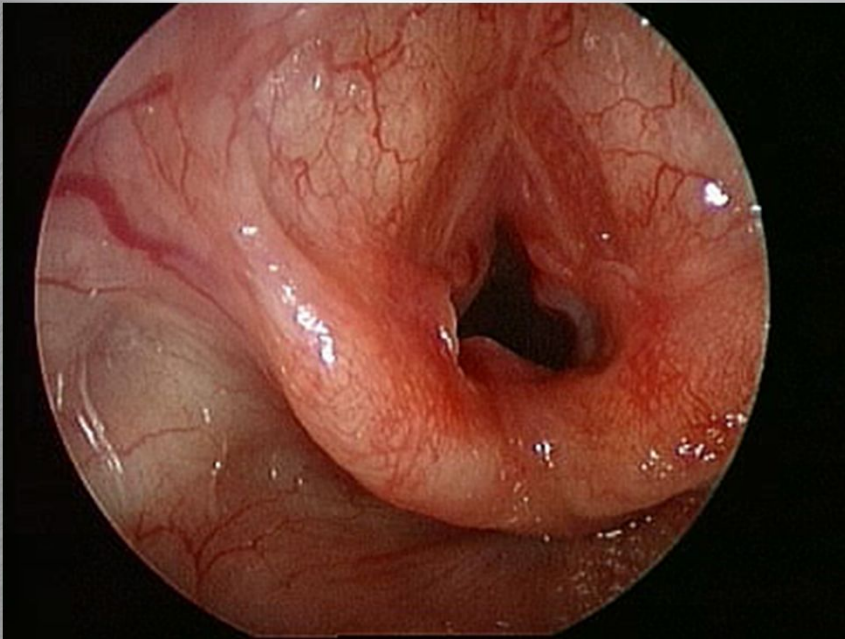


# Division of thin stenosis

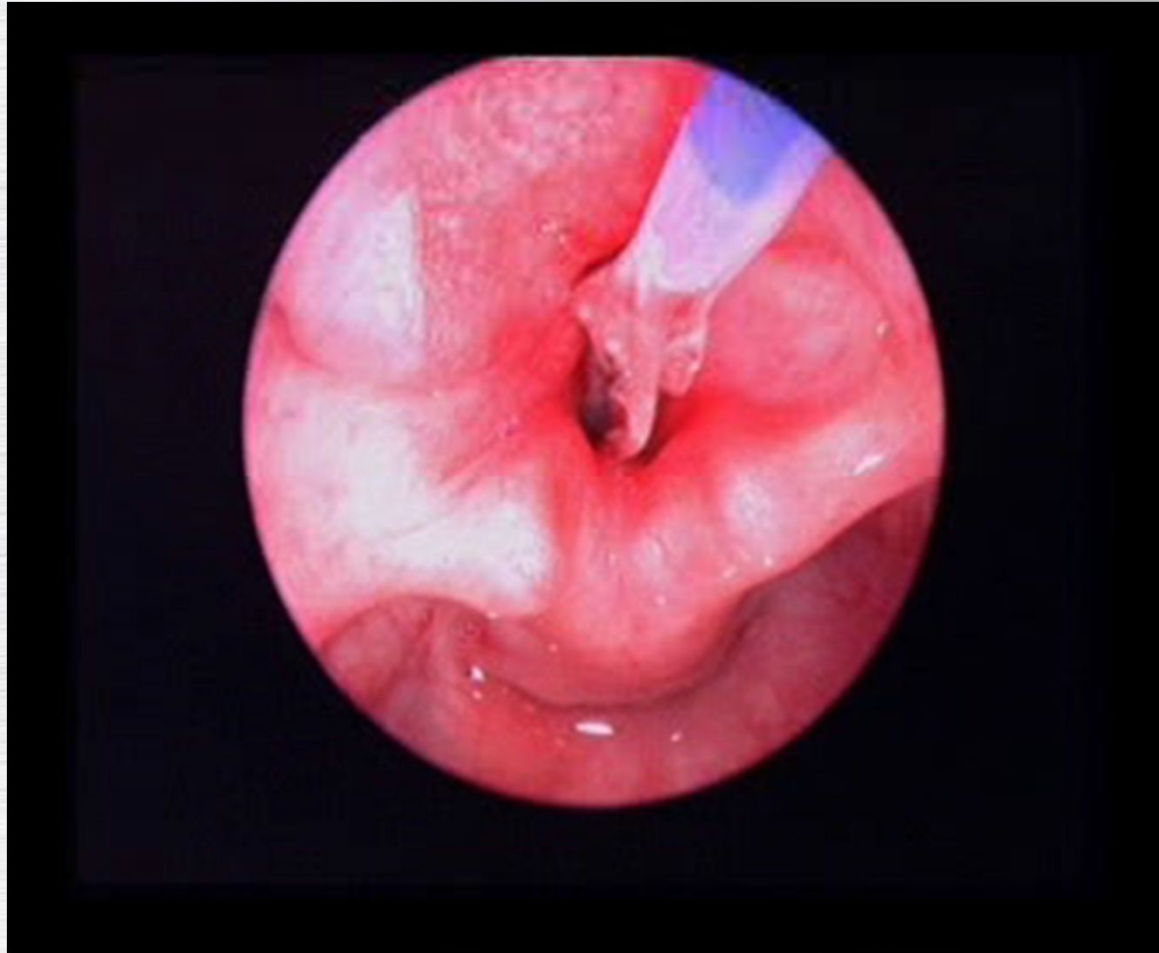




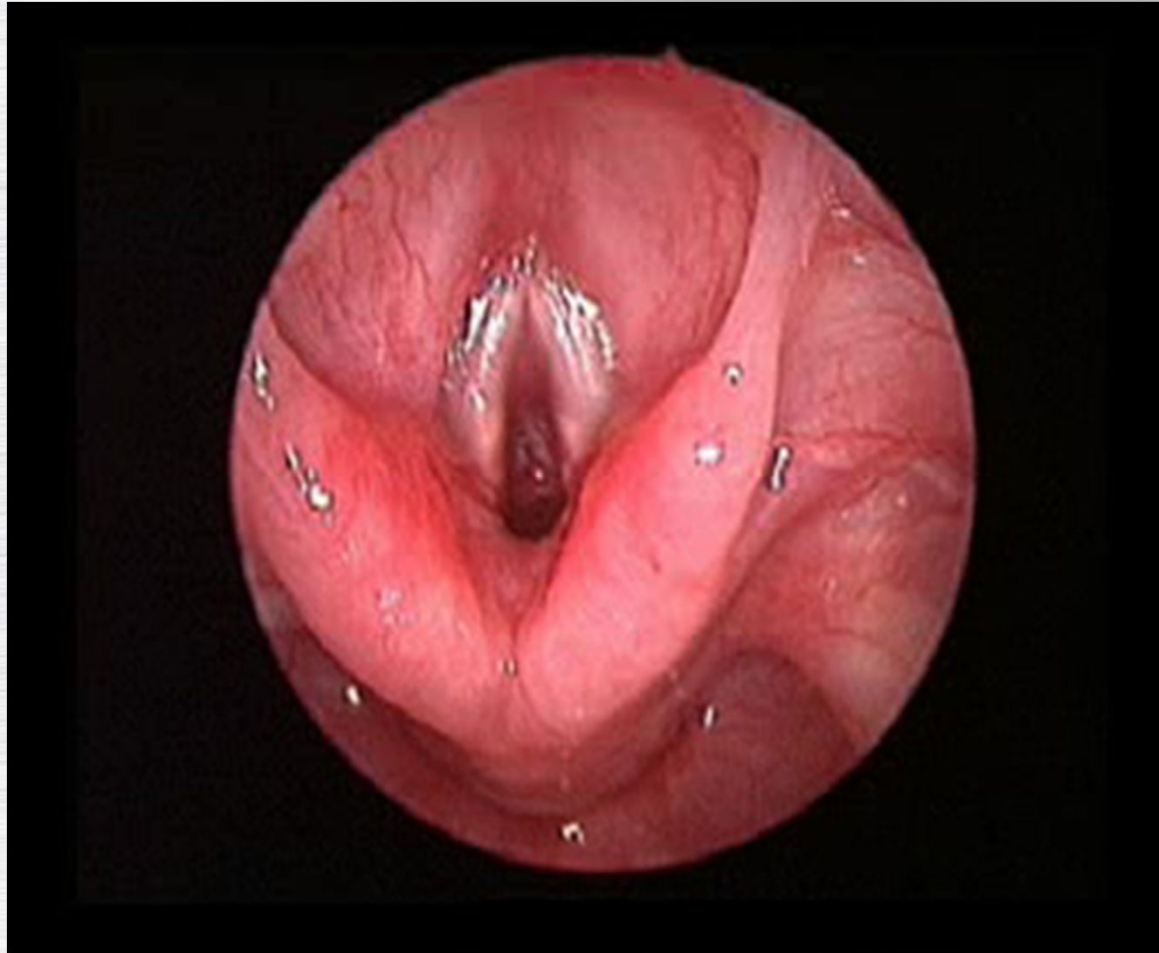
# Endoscopic Decompression Of Edematous Larynx



# Balloon radial dilatation




## Microdebrider for suprastomal granulations



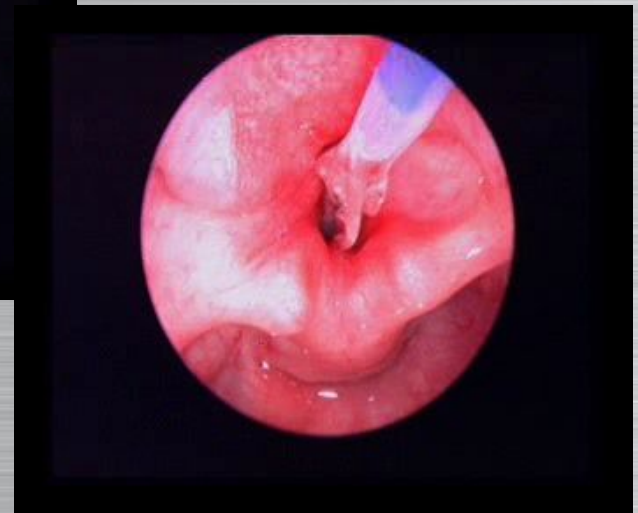
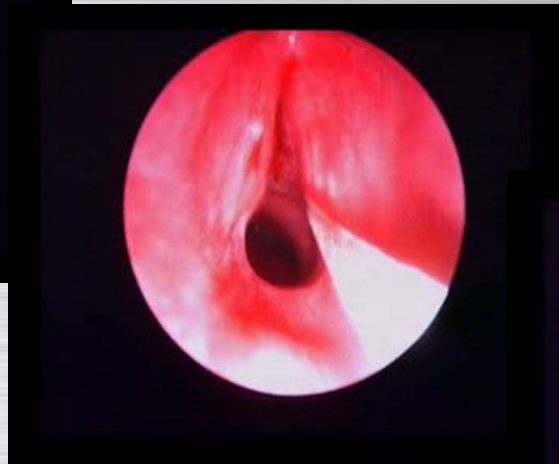
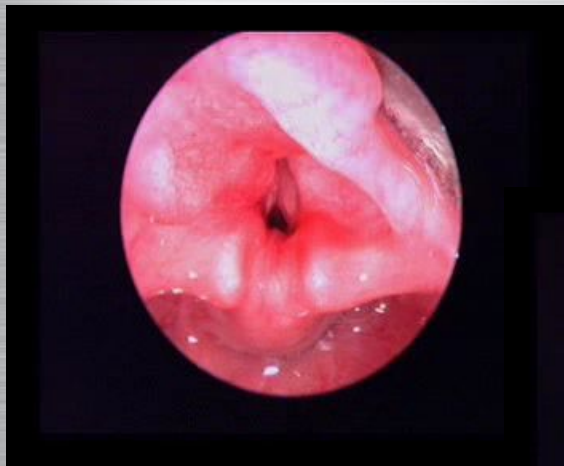# AN: ex-prem, failed extubation

Endoscopic cricoid split



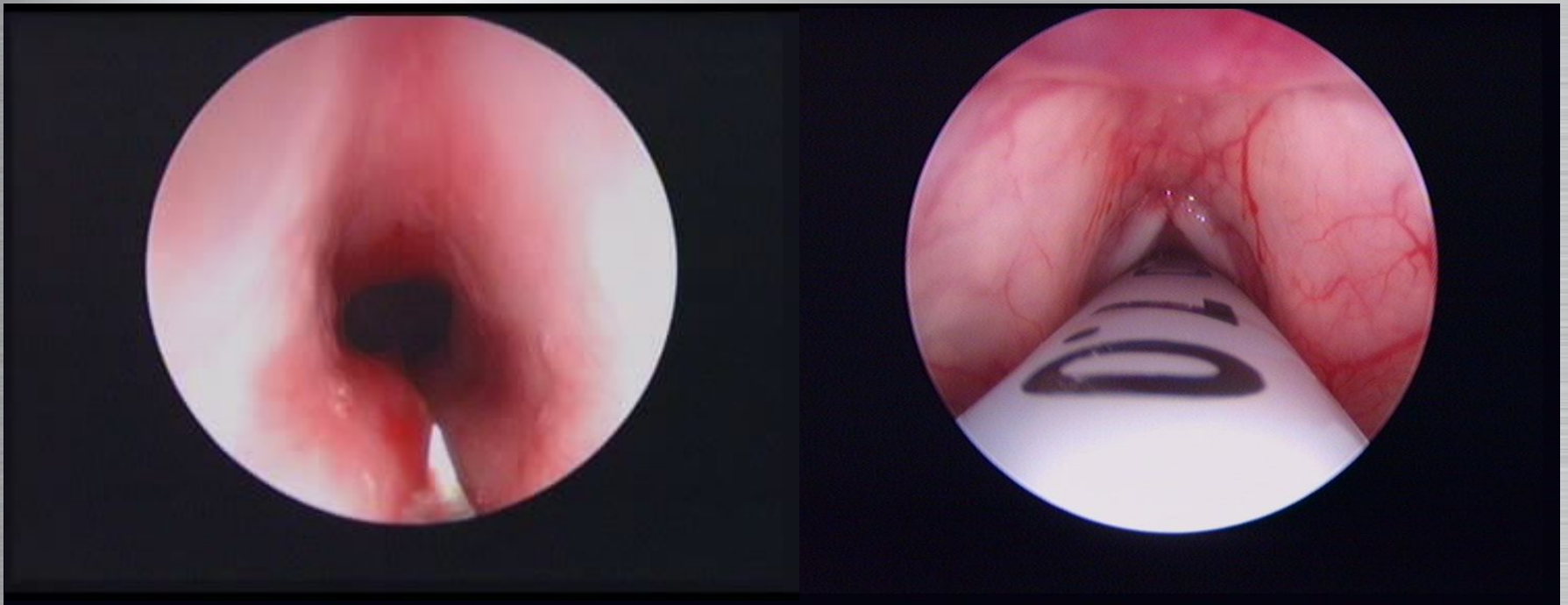
# NS ex-prem, failed extubation

Endoscopic cricoid split

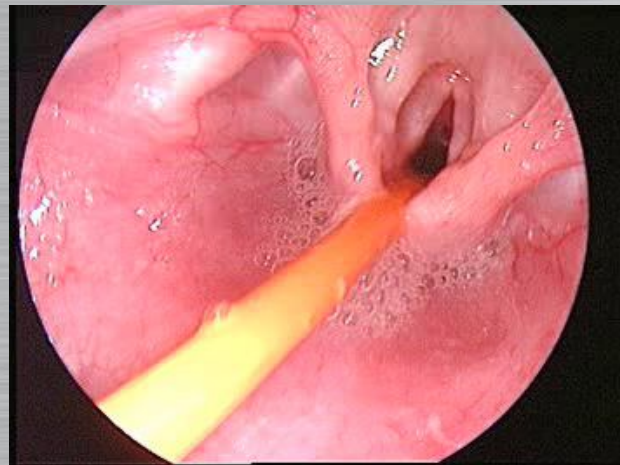
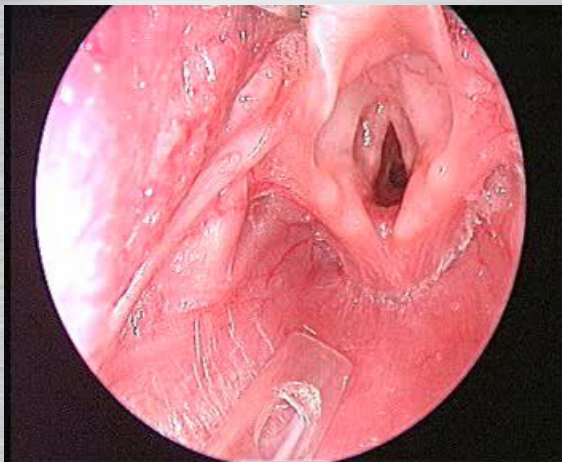




**AK:** 15 years old, intubated for Guillain Barré

Balloon/division to allow  
decannulation

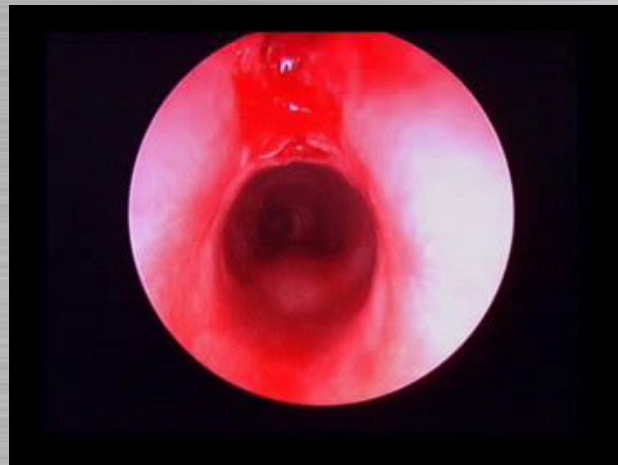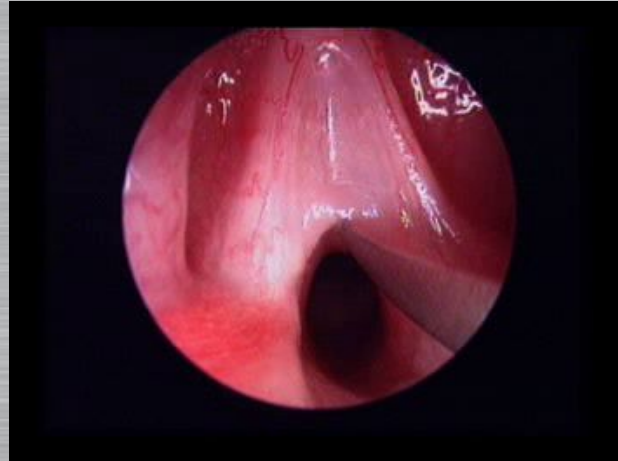


# EB: ex prem with stridor



# MK: 2 year old with stridor

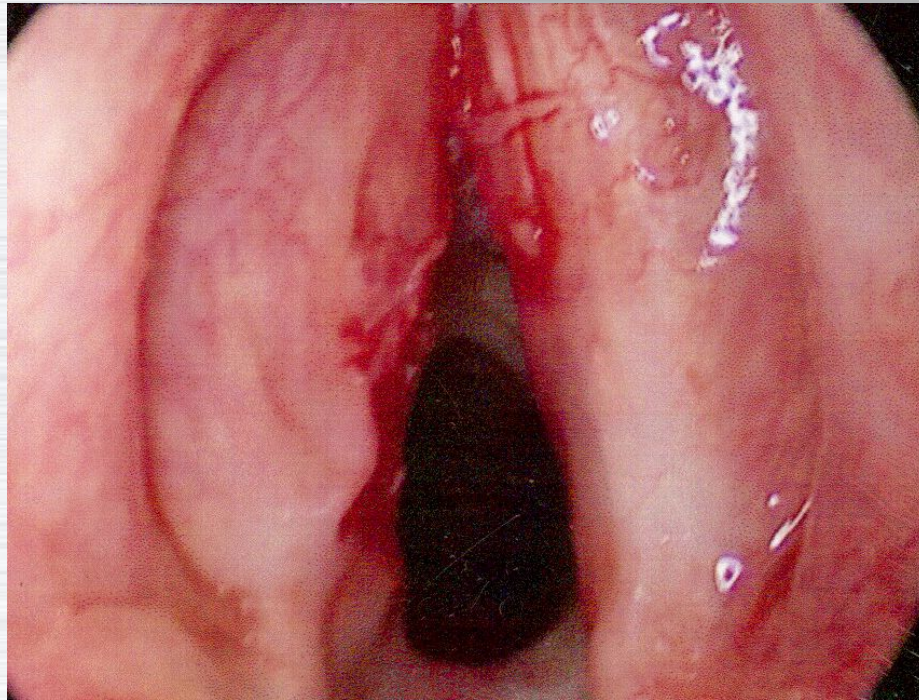
Unplanned division of  
congenital web stenosis





MAE 5 year old

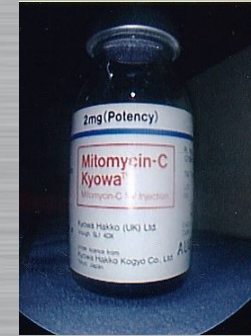
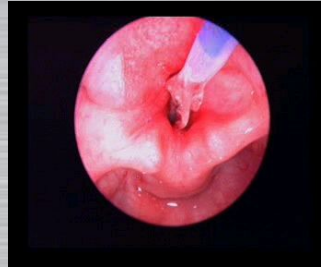
Wedge resection of recurrent web



# Later techniques to prevent restenosis

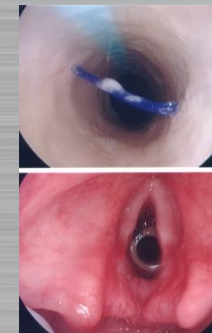
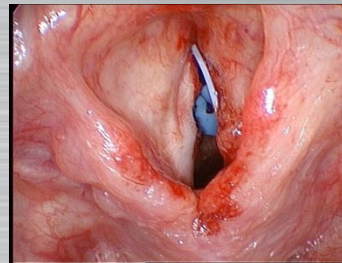
# Later Techniques

Repeat radial dilatation  
Mitomycin/Steroids



Lateralisation sutures

Montgomery T-Tube  
silastic keels  
tube stents



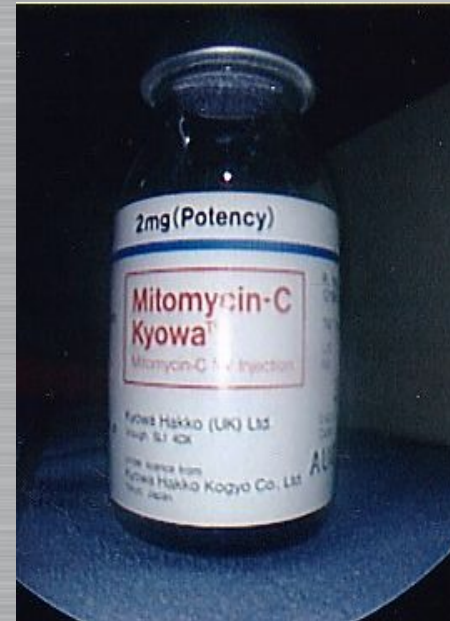
Wedge resection  
Endoscopic grafts

# Mitomycin C

*Antineoplastic antibiotic - acts as an alkylating agent by inhibiting DNA and protein synthesis*

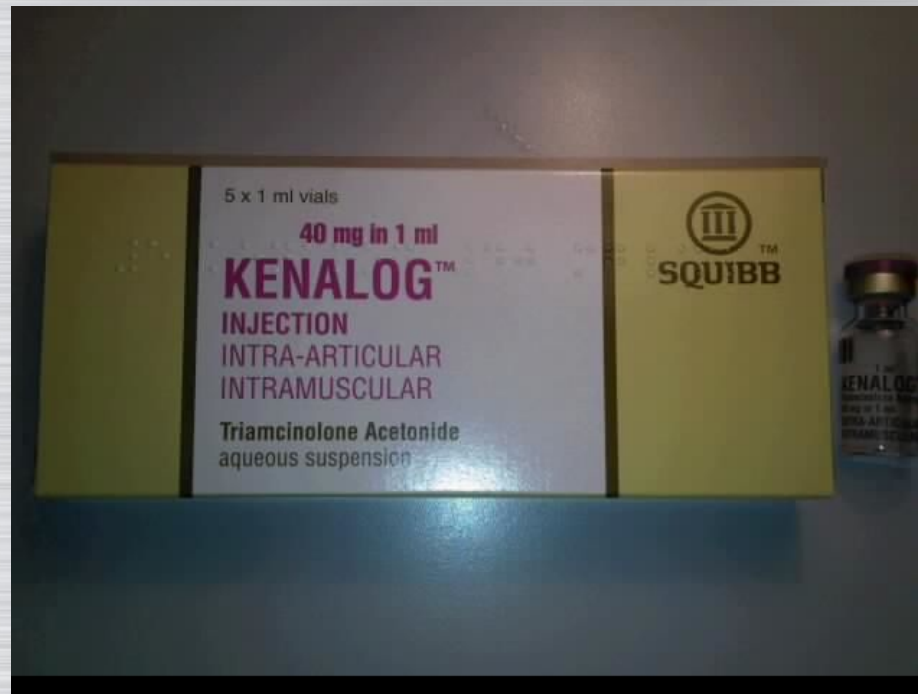*Dose 0.4 to 4 mg/ml*

*2 mg/ml*



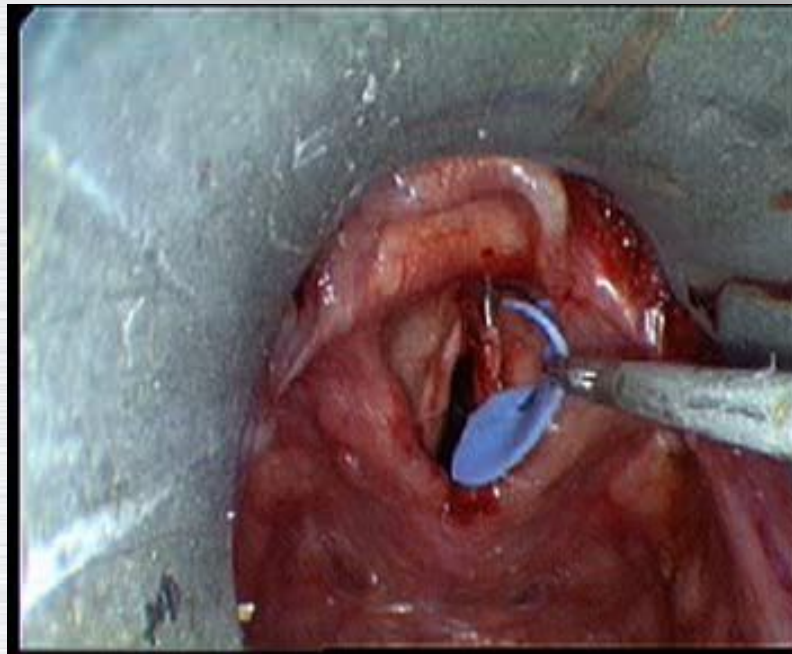
# Triamcinolone Injection

*40 mg in 1 ml*

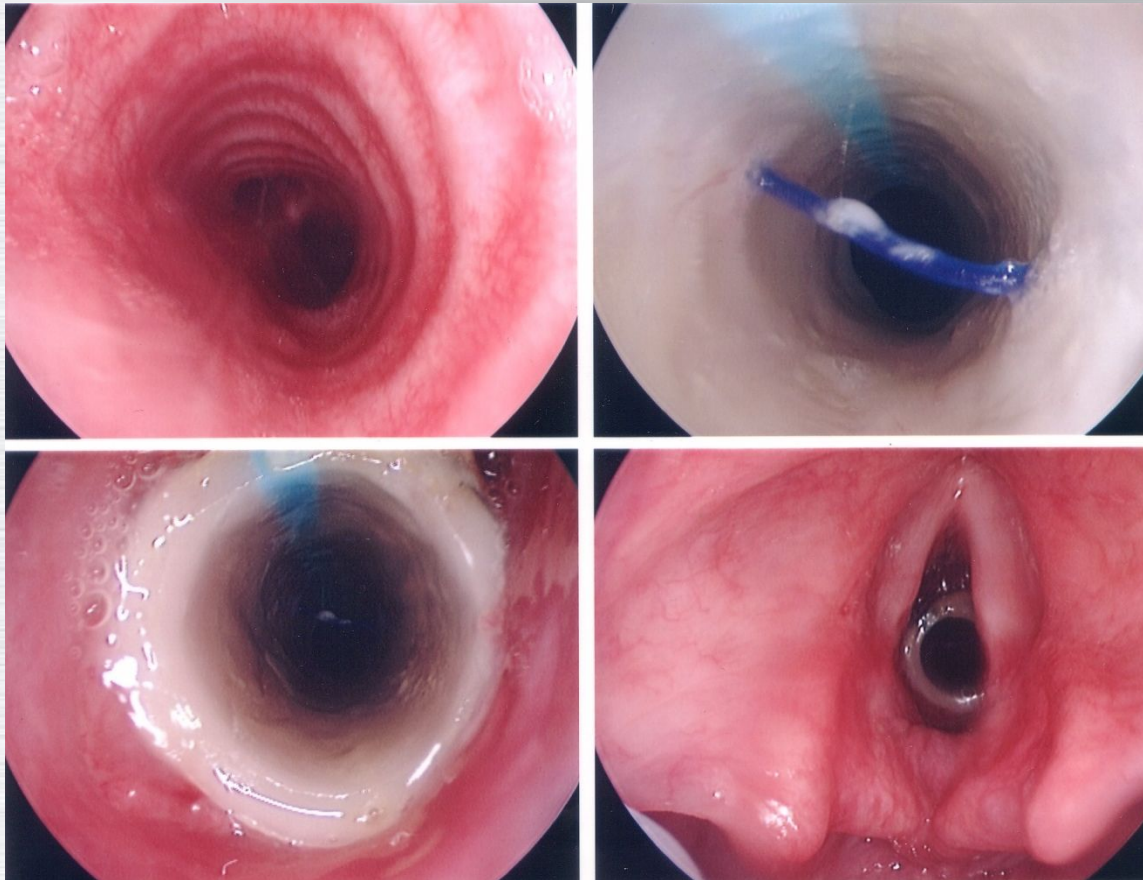


# AZ: 8 years, anterior web following laser for papilloma

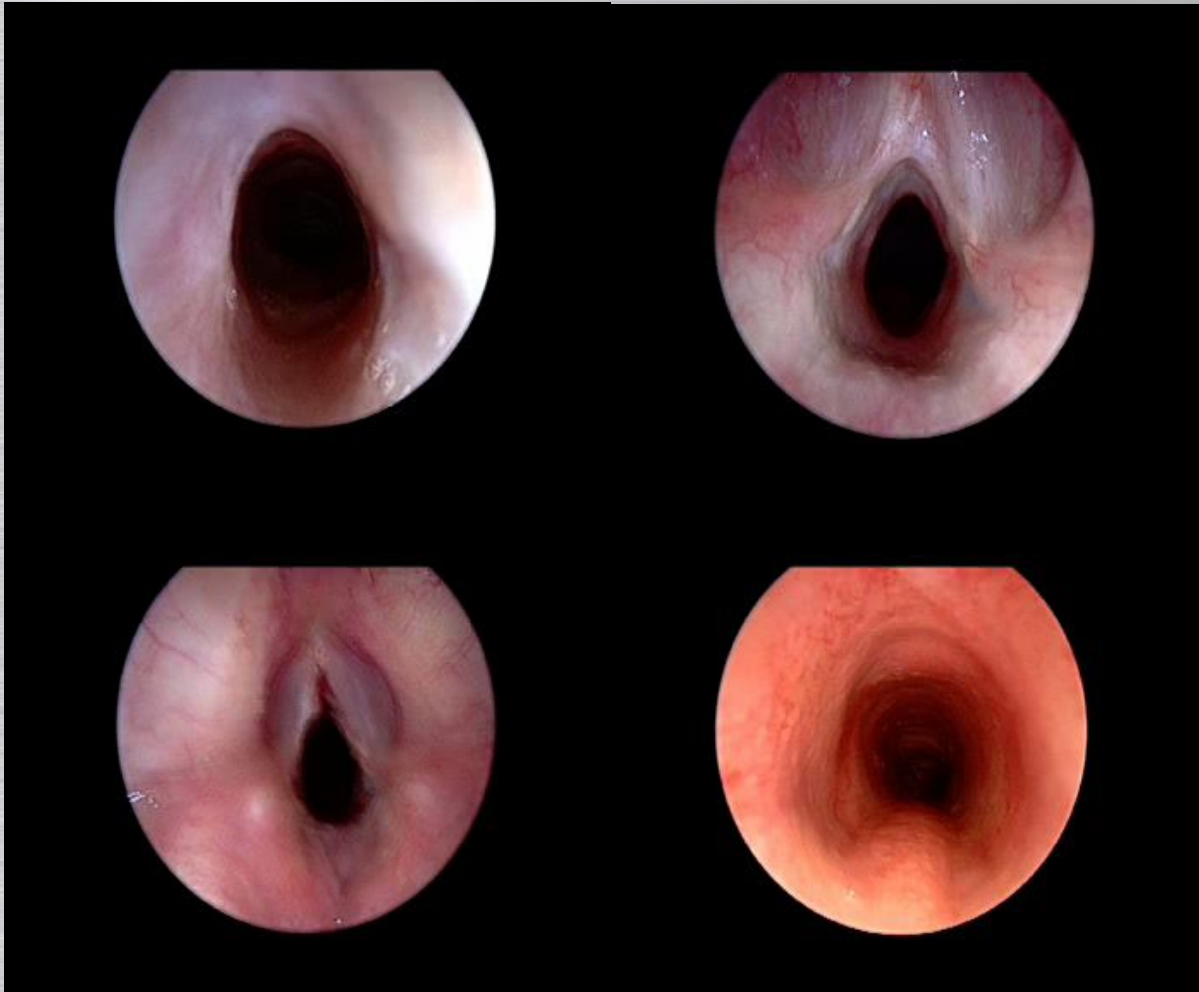Division with insertion of silastic stent



# Endoscopic Insertion of Endolaryngeal Stent

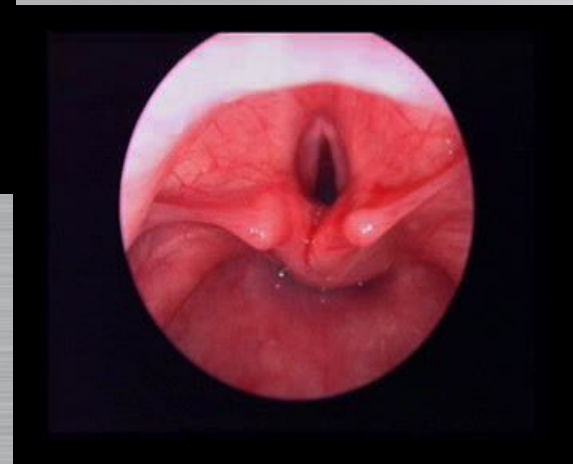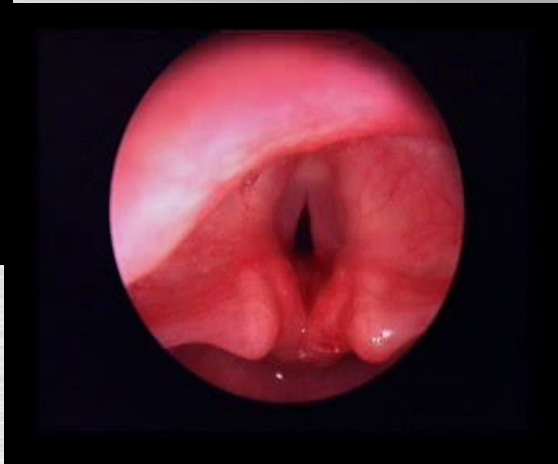
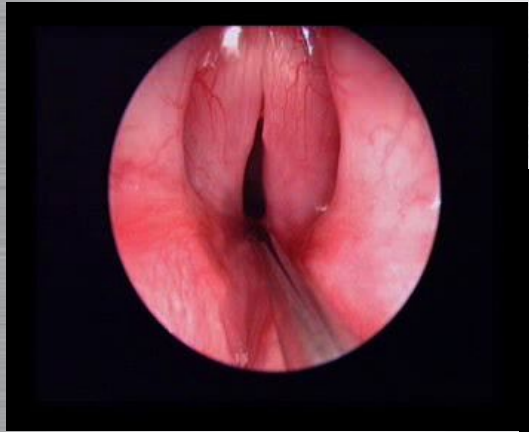


EJ: 12 years old, failed laser division of web stenosis



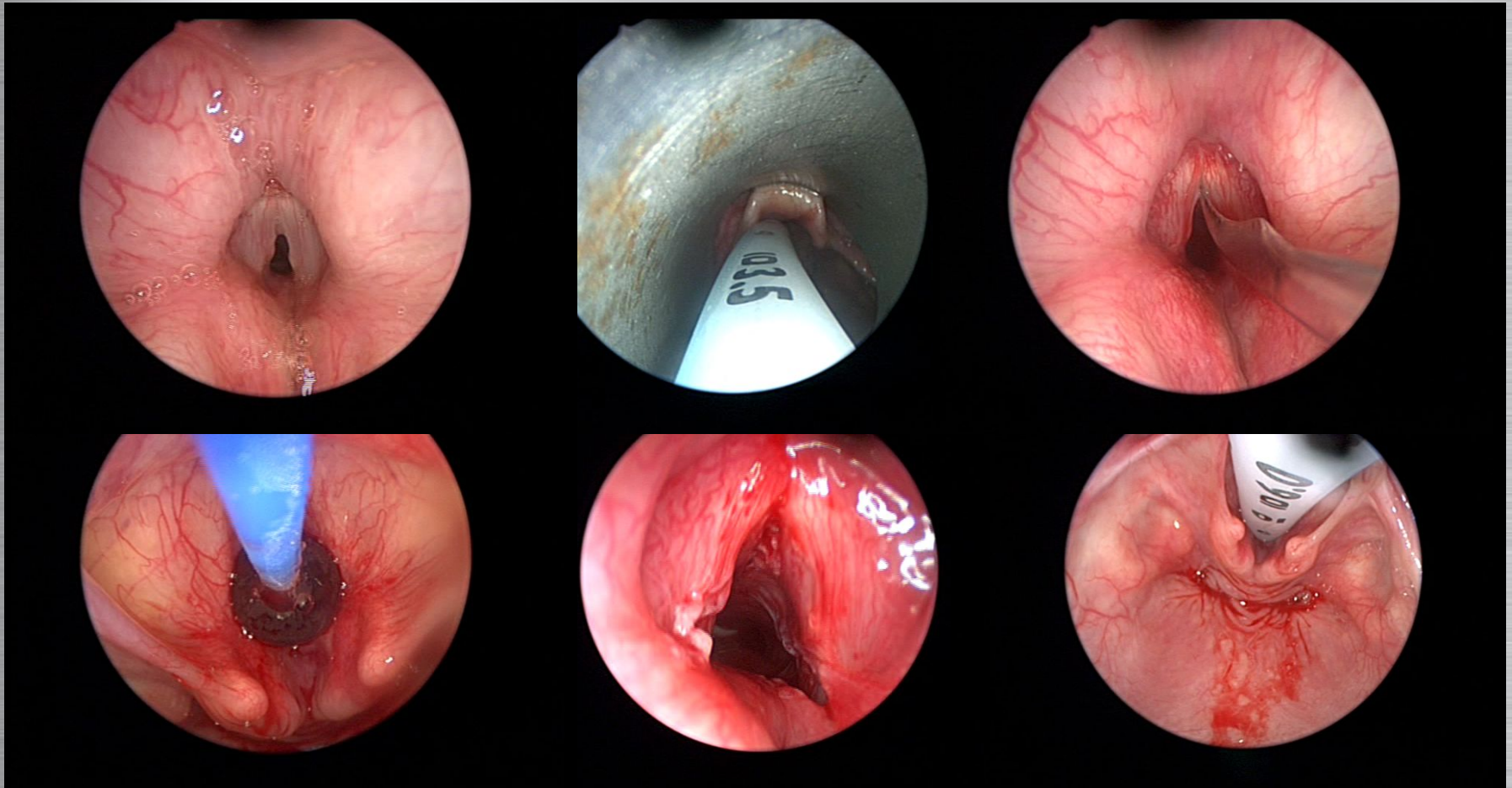


# RC: 12 years skiing accident



# CN: 10 years RTA

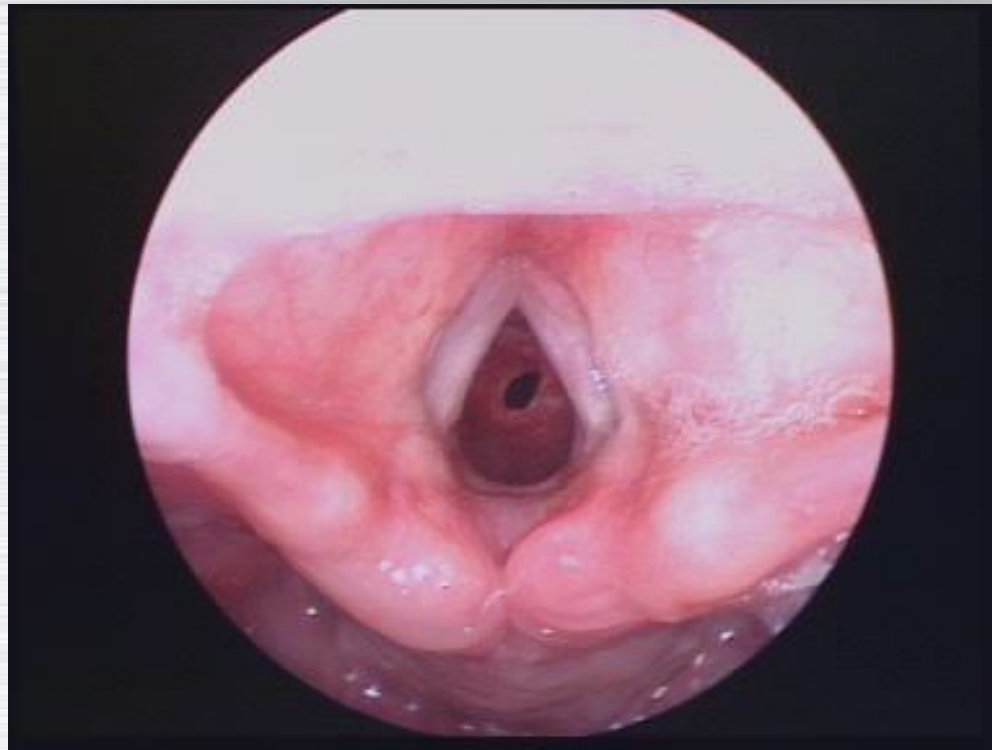
Division of interarytenoid scar, anterior web and subglottic stenosis



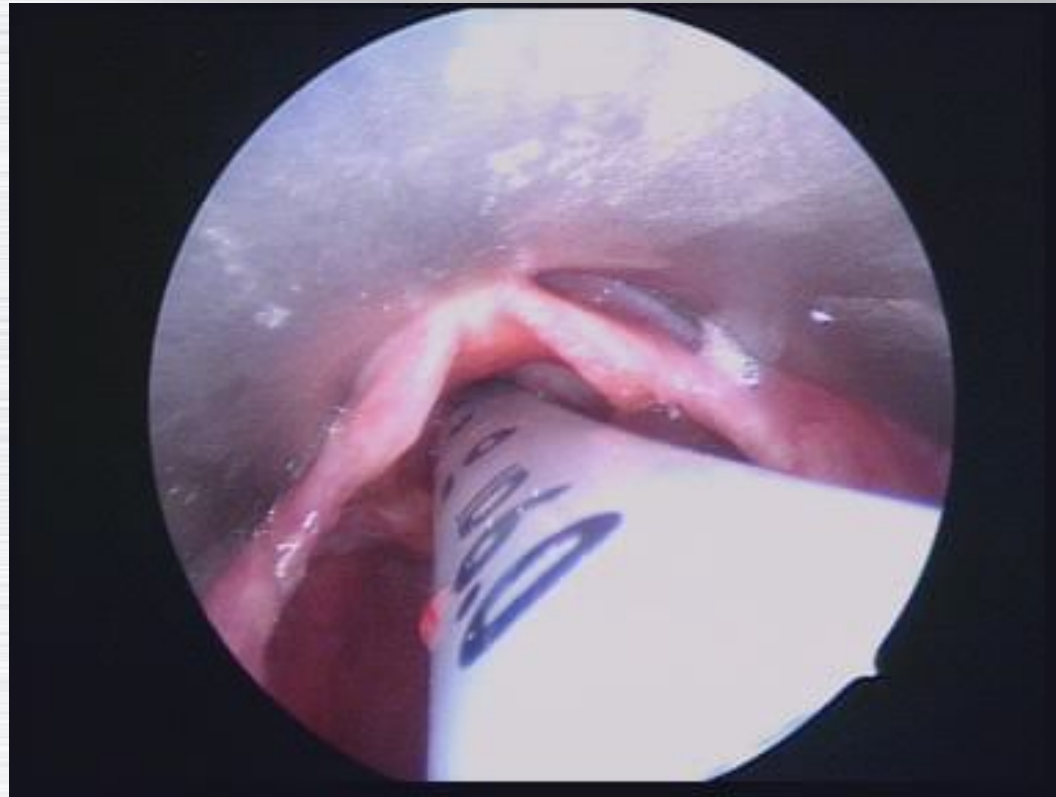
# MK: Downs, microtrachea

Cricotracheal resection, multiple stents

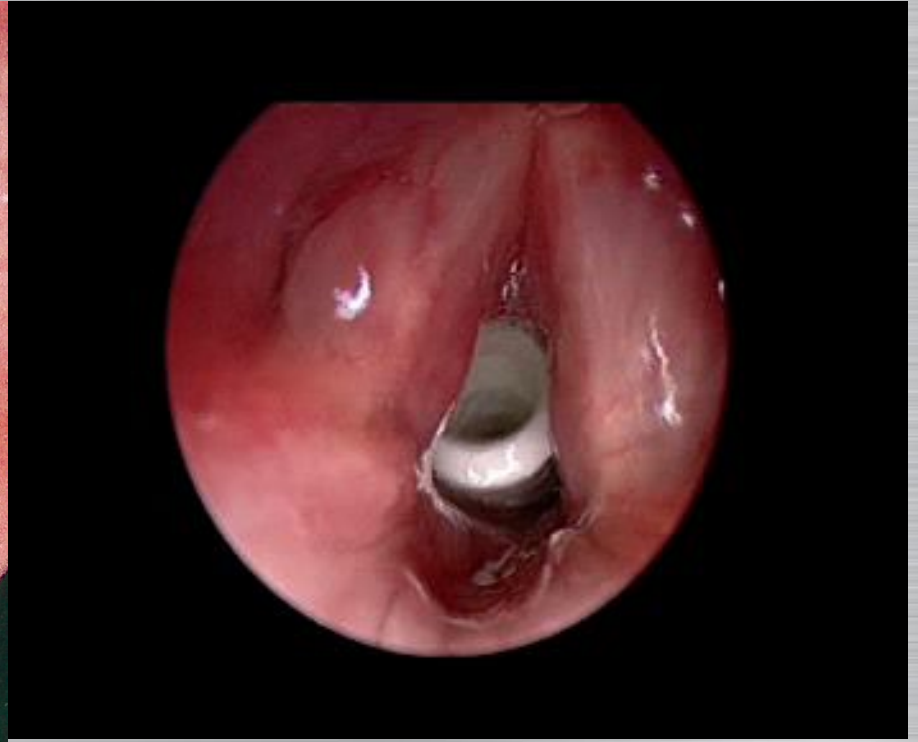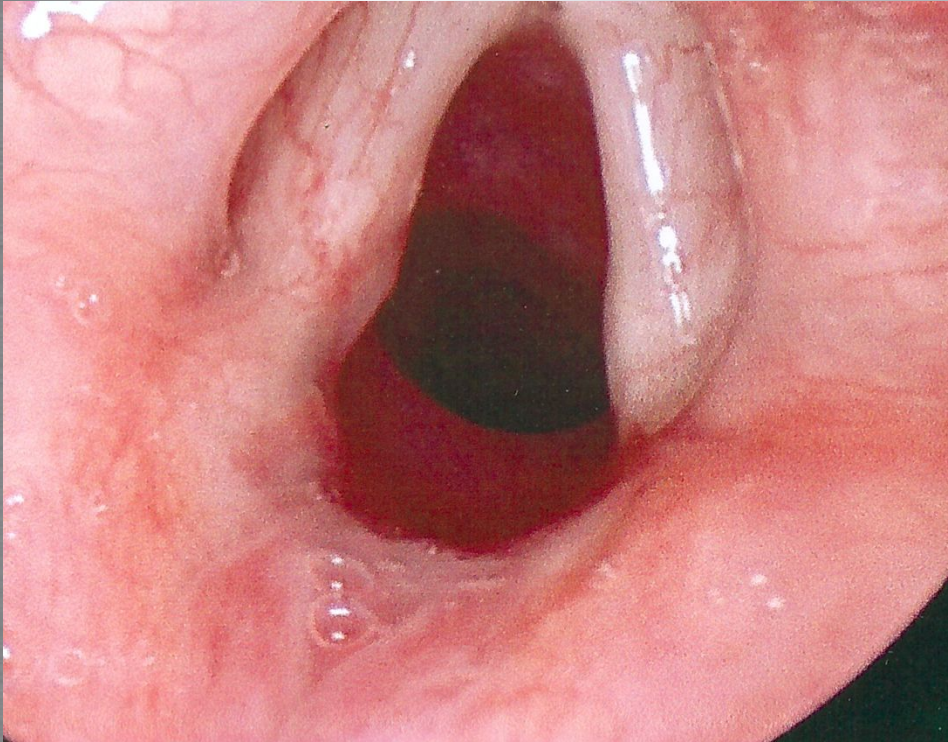
Steroid injection controlled mid tracheal stenosis



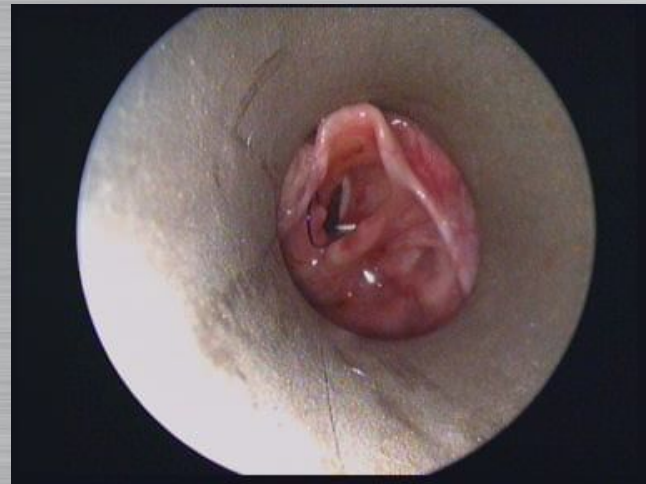
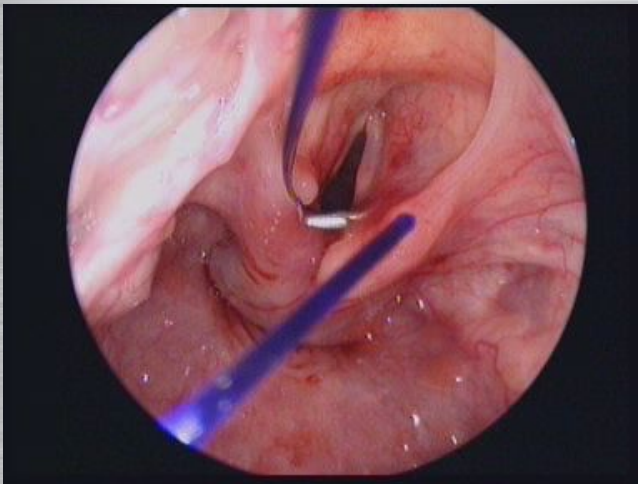
# MK: Downs, microtrachea



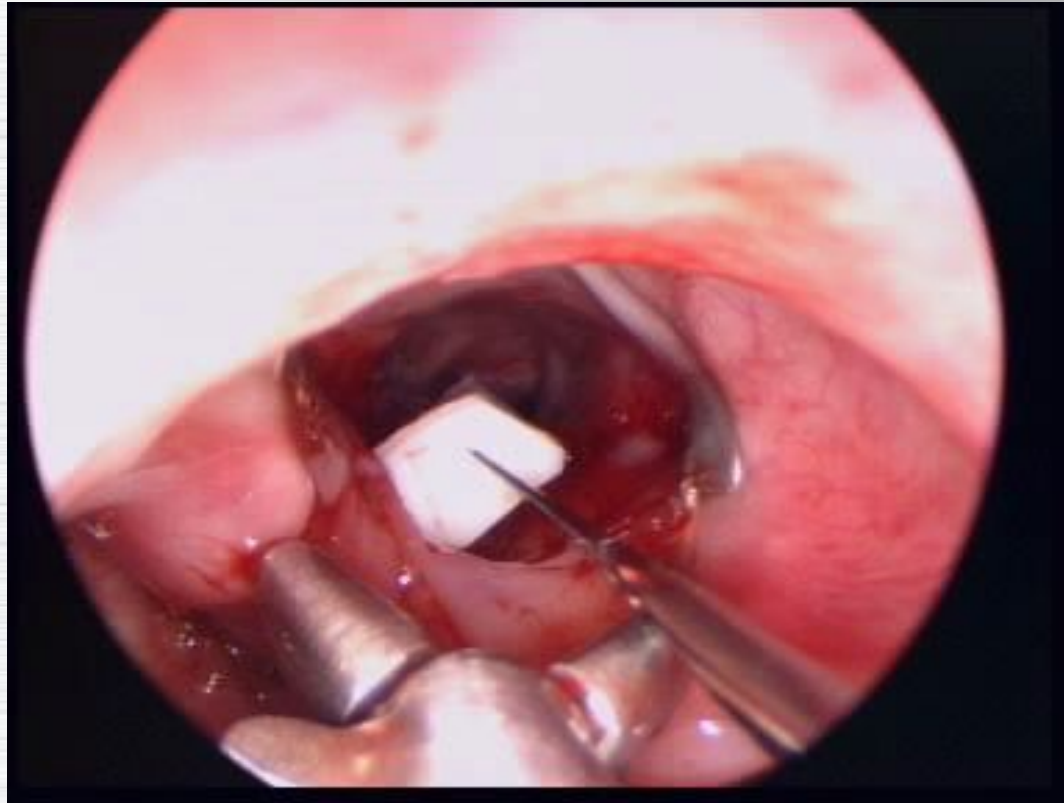
# T tube to prevent restenosis

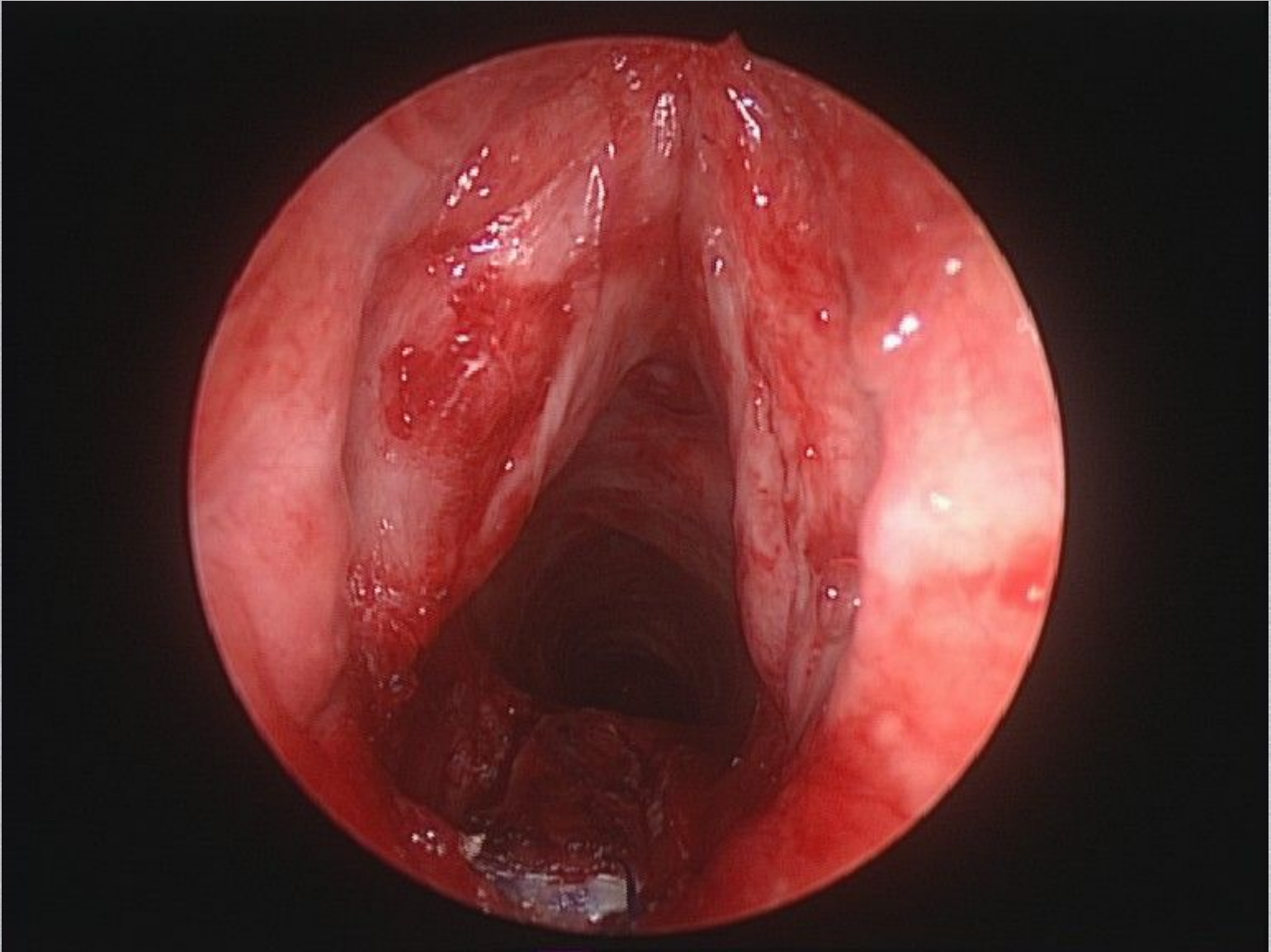


# Lateralisation suture

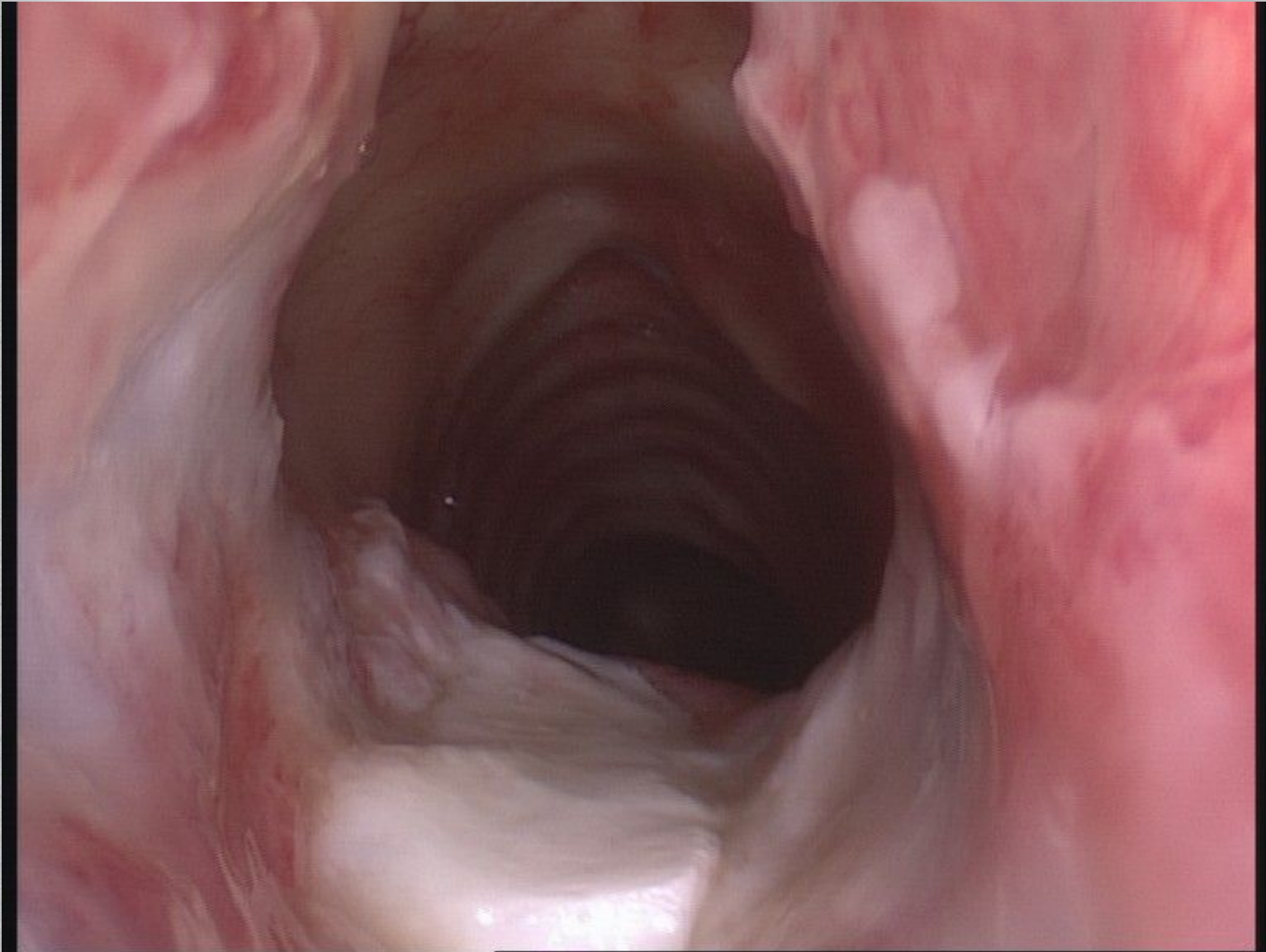


# Endoscopic posterior graft









# Numbers

10 years

GOS

6256

MLB/Endoscopies

694`

Endoscopic treatment

351

Non balloon treatments

28

Endoscopic cricoid split

343

Balloon Dilatation

6

Endoscopic posterior grafts

# Summary

Advanced endoscopic procedures may reduce the need for open surgery.

The indications, risks and benefits need to be determined

My experience has been mostly positive

- No major complications

- A few notable success stories

- Time and cost a consideration

# DATE FOR YOUR DIARY

**Saturday 31st May – Tuesday 3rd June  
2014**

The Convention Centre, Dublin, Ireland



12<sup>th</sup> INTERNATIONAL CONGRESS OF THE EUROPEAN SOCIETY  
OF PEDIATRIC OTORHINOLARYNGOLOGY



[www.albert.uk.com](http://www.albert.uk.com)

Presentations

Images

Videos